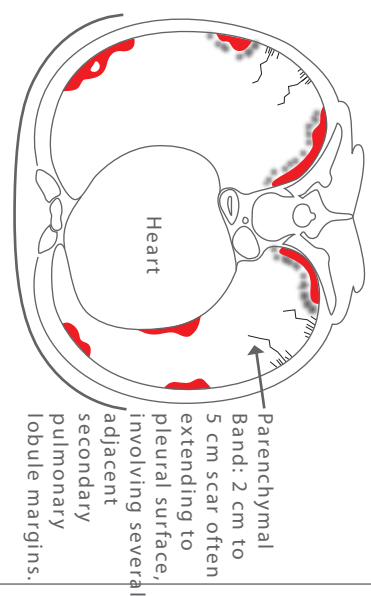
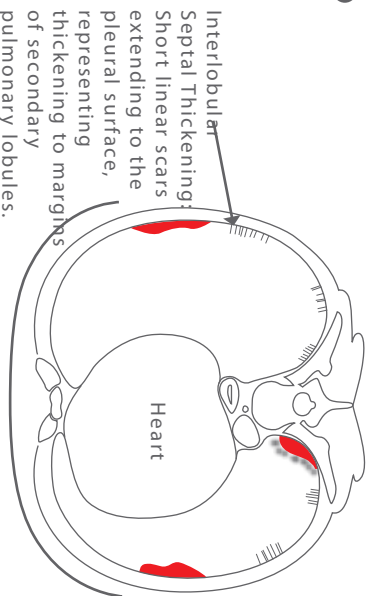
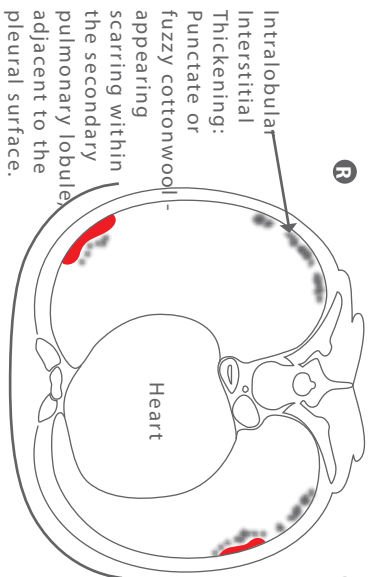
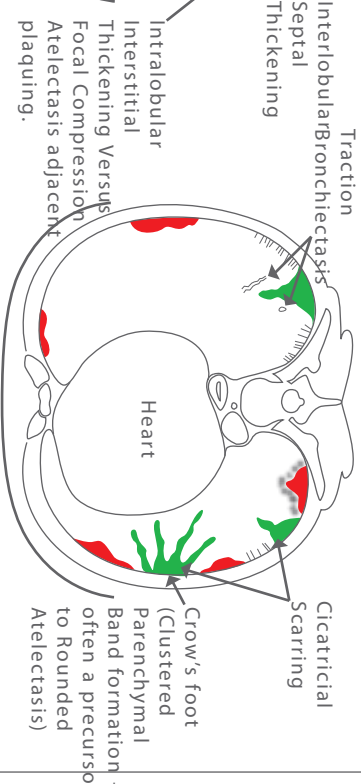
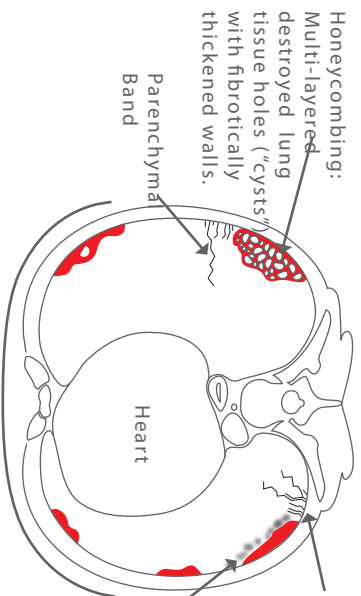
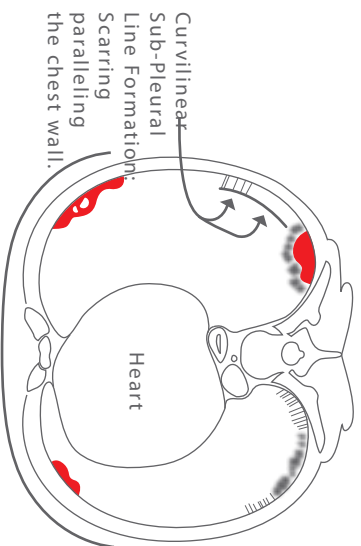


Intralobular Interstitial Thickening
(Intralobular/Core Changes)



Curvilinear Sub-Pleural Line Formation



Interlobular Septal Thickening

Parenchymal Bands

Honeycombing

Cicatricial Scarring
(Focal or Benign Fibrotic Masses)

Rounded Atelectasis

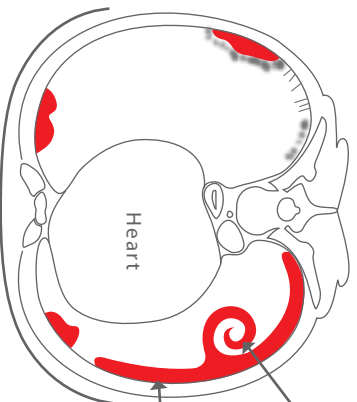
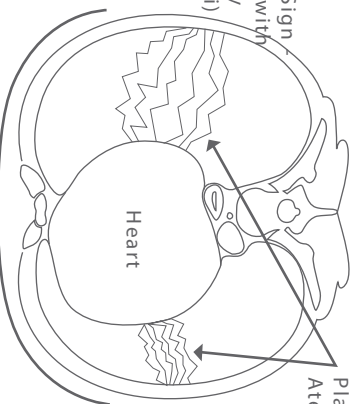


Plate-Like Atelectasis/Scarring



Lung Carcinoma

