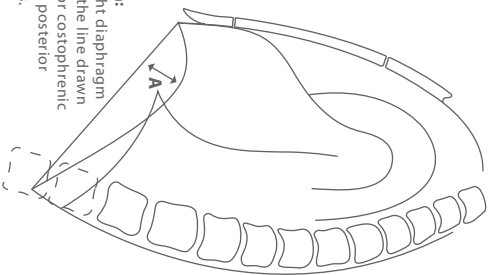
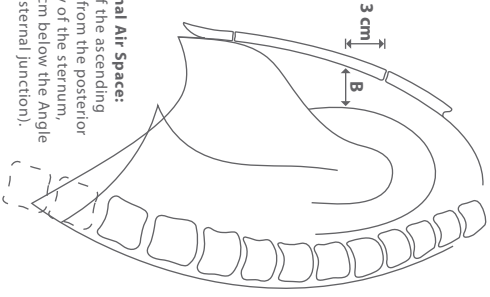
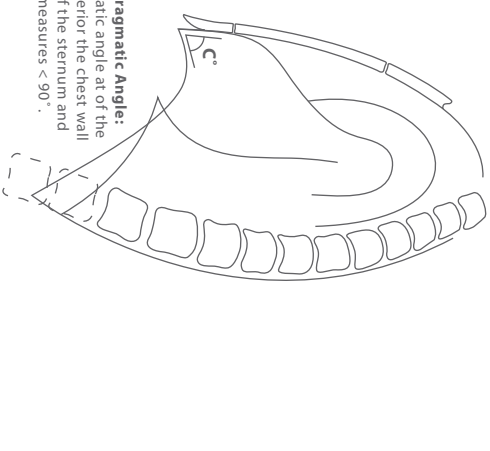


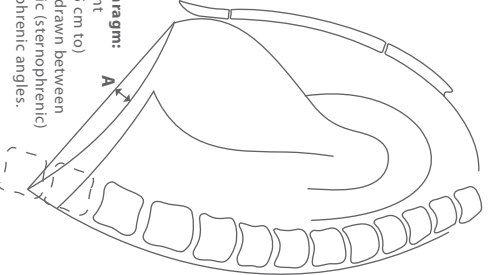
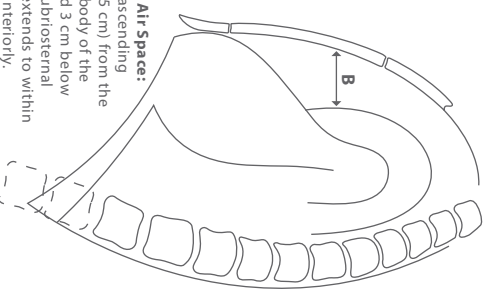
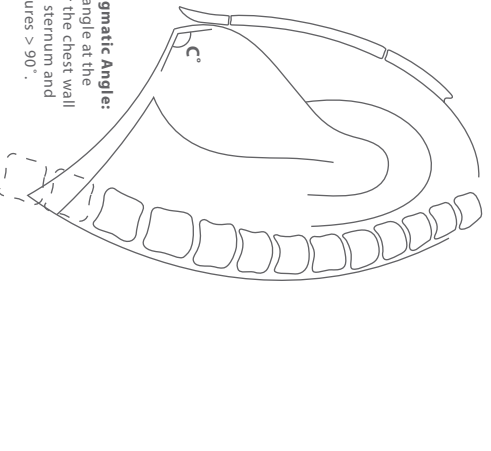
Lateral Chest X-Ray Changes in Emphysema

Normal

<p>Height of Diaphragm</p>  <p>Normal Diaphragm: The dome of the right diaphragm lies > 1.5 cm above the line drawn between the anterior costophrenic (sternophrenic) and posterior costophrenic angles.</p>	<p>Depth of Retrosternal Air Space</p>  <p>Normal Retrosternal Air Space: The anterior wall of the ascending aorta lies < 2.5 cm from the posterior margin of the body of the sternum, when measured 3 cm below the Angle of Louis (manubriosternal junction).</p>	<p>Sternodiaphragmatic Angle</p>  <p>Normal Sternodiaphragmatic Angle: The sternodiaphragmatic angle at of the junction between anterior the chest wall at the lower margin of the sternum and the right diaphragm measures < 90°.</p>
---	--	---

Emphysema

I. Hyperaeration

<p>Flattening of Diaphragm: The dome of the right diaphragm lies (< 1.5 cm to) < 2.7 cm above line drawn between anterior costophrenic (sternophrenic) and posterior costophrenic angles.</p> 	<p>Increased Retrosternal Air Space: The anterior wall of the ascending aorta lies > 2.5 cm (to 4.5 cm) from the posterior margin of the body of the sternum, when measured 3 cm below the Angle of Louis (manubriosternal junction) and the lung, extends to within 3 cm of the diaphragm anteriorly.</p> 	<p>Increased Sternodiaphragmatic Angle: The sternodiaphragmatic angle at the junction between anterior the chest wall at the lower margin of the sternum and the right diaphragm measures > 90°.</p> 
--	---	--